

AmbioDisk™

Office Procedure: Sutureless, overlay use of AmbioDry2™ Amniotic Membrane on the ocular surface

Conventional Uses

- Non-Healing Epithelial Defects
- Neurotrophic Ulcerations
- Corneal Erosions
- Acute Chemical/Thermal Burns
- Post-Infectious Keratitis (herpetic, vernal, bacterial)

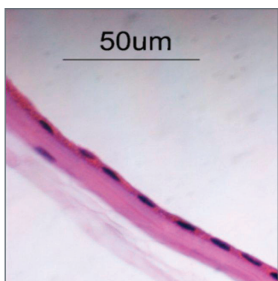
Surgical Pearls

For optimal adherence, maintain a dry ocular surface during placement of the Ambio graft. In order to prevent bunching of the graft, avoid sliding the lens from side-to-side during positioning.

Naturally, small air bubbles and folds in the Ambio graft may be noted immediately following placement. The bubbles and creases – along with the opacity of the Ambio graft – will resolve over a 1-2 day time period, leaving a normal translucent appearance.

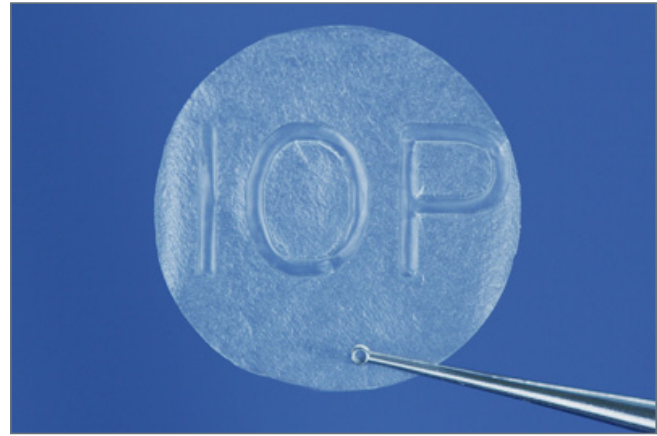Typically, the Ambio graft will absorb 5-7 days following placement.

Tarsorrhaphy is not required.



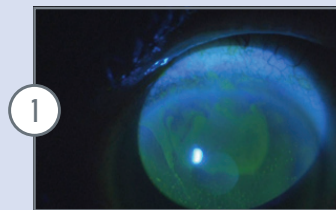
More Biostructurally Intact

- Contains an intact epithelial, columnar cell matrix on the surface of the basement membrane
- Maintains an intact dense basement membrane
- Provides a loose collagen layer bordered by retained fibroblasts



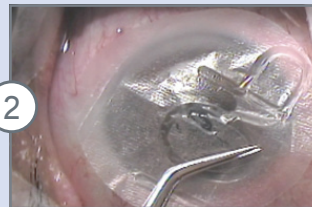15mm AmbioDry2 Disk

Case Technique: Persistent Epithelial Defect



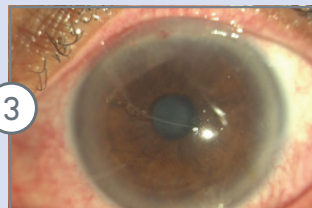
1

Patient presented with a large, superior persistent epithelial defect, secondary to previous melanoma excision with topical mitomycin C. Previous treatment with bandage contact lens yielded insignificant healing.



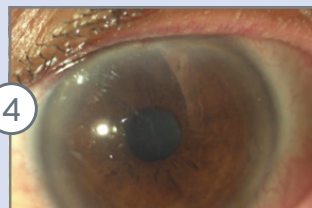
2

Topical anesthesia was applied. The area of the defect was denuded. A 15mm AmbioDry2 amniotic membrane graft was placed on the ocular surface – to cover the entire cornea and limbal regions. No tarsorrhaphy required.



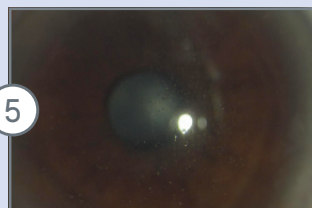
3

Slit lamp image immediately after the procedure notes small bubbles and creases in the AM graft. Light haze indicates intact presence of the graft. The patient is comfortable and functioning.



4

At 9-day post-op, fragmented globules of the AM graft are noted – at the interface of the contact lens and the cornea. The defect appears to have healed. The eye remains comfortable and functional.



5

At 30-day post-op, slit lamp image shows spherical particles of retained amnion between lens and corneal surface. Slit lamp image with fluorescein stain and cobalt blue filter shows pooling but not staining with fluorescein, demonstrating that epithelium has healed. Pooling of stain is also evident elsewhere in the cornea in small, circular indentations in the epithelium where remnants of the amniotic membrane remained until the contact lens was removed.

AmbioDisk™

CODE	DIMENSIONS	THICKNESS
AD-5150	AmbioDry ² (1.5 mm disk)	35 microns
AF-1150	Ambio5 (15 mm disk)	100+ microns

Additional Amiotic Membrane Technologies

AmbioDry²

CODE	DIMENSIONS	THICKNESS
AD-5120	AmbioDry ² (1.5 x 2 cm)	35 microns
AD-5230	AmbioDry ² (2 x 3 cm)	35 microns
AD-5440	AmbioDry ² (4 x 4 cm)	35 microns

Ambio5

CODE	DIMENSIONS	THICKNESS
AF-1120	Ambio5 (1.5 x 2 cm)	100+ microns
AF-1230	Ambio5 (2 x 3 cm)	100+ microns
AF-1440	Ambio5 (4 x 4 cm)	100+ microns

Amniotic Membrane Reimbursement CPT Codes

CPT 65778	Placement of amniotic membrane on the ocular surface for wound healing; self retaining
-----------	--

The relevance of the reimbursement codes depends on indications of use and geographic region. Please use this hotline to determine what the guidelines are for your area. IOP Reimbursement Hotline 888.700.9005

Tissue Safety

All tissues recovered meet stringent specifications related to donor screening and testing. Ambio5 and AmbioDry2 allografts are procured and processed according to standards established by the American Association of Tissue Banks (AATB) and the United States F.D.A. and are subject to unyielding high standards to ensure tissue safety.



3184-B Airway Avenue
Costa Mesa, CA 92626 USA

Tel 714.549.1185
Fax 714.549.0557
ambio@iopinc.com

Customer Service
800.535.3545
iopinc.com